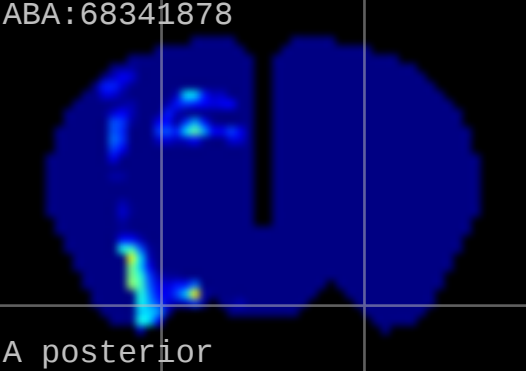


ABA : 68341878

A posterior

A brain scan image, likely an fMRI or PET scan, showing activation in the left hemisphere. The image is a grayscale slice of a brain, with a vertical line indicating the midline. The left side of the image (patient's right) shows several areas of activation, with the most prominent being a large, bright yellow and red region in the posterior parietal/occipital area. Other smaller, less intense activation spots are visible in the superior and middle temporal regions. The right side of the image (patient's left) shows minimal to no activation. The text 'ABA : 68341878' is at the top, and 'A posterior' is at the bottom.